

# Subconjunctival Emphysema After Descemet's Stripping Automated Endothelial Keratoplasty (DSAEK)

Takeshi Ide\*, George D. Kymionis, Sonia H. Yoo and Terrence P. O'Brien

*Bascom Palmer Eye Institute, University of Miami, Miami, FL, USA*

**Abstract:** DSAEK has recently evolved as a preferred method in place of PKP. After DSAEK, we experienced subconjunctival emphysema, decreased air bubble in the AC and low IOP. This could lead to complications, higher rate of dislocation or infection. We should control the wound closure with suture when in doubt.

## INTRODUCTION

Penetrating keratoplasty (PKP) has long been the procedure of first choice for replacement of diseased endothelium. In recent years, however, attempts have been made to replace only the endothelial layer [1,2]. Descemet's Stripping Automated Endothelial Keratoplasty (DSAEK) has recently been popularized [3-5]. Fewer complications are expected when posterior corneal tissue is selectively replaced, because full thickness transplantation can be complicated by a variety of postoperative problems.

In place of running or interrupted sutures in PKP, in DSAEK we inject air into the anterior chamber to push the donor cornea against the host stroma. Air is known to cause damage on corneal endothelium [6,7] and, therefore, some doctors aspirate air several minutes after air injection. Most doctors, however, leave the air in the anterior chamber (AC) as long as possible, in case DSAEK donor button dislocates in the AC. Air maintenance in the anterior chamber is critical for this surgery within the first few hours, especially after rebubbling.

In this case report, we observed sub conjunctival air bubbles and reduced AC air bubbles on post-operative day 1.

## CASE REPORT

An 85 year-old lady with Fuch's dystrophy had DSAEK surgery on her left eye at our center. She had previous cataract surgery and her intraocular lens was centered in her posterior capsule. Her ophthalmologic and systemic general condition was otherwise normal.

The DSAEK surgery was routine and uneventful. At the end of DSAEK surgery, we injected air into the anterior chamber.

The next day, slit lamp examination showed subconjunctival emphysema in the temporal-inferior part of the left eye. The DSAEK tissue in the anterior chamber had wrinkles but adhered well. The anterior chamber was about 50% filled with air. This reduction was faster than usual. The intraocular pressure (IOP) was 14mmHg and 7mmHg in her right

and left eye respectively. The ocular findings were otherwise normal. The entry of paracentesis incision in the temporal-inferior part could be seen just over the sclera-subconjunctival area (Fig. 1).

## DISCUSSION

In this patient, we observed a case of subconjunctival emphysema, decreased air bubble in the AC and low IOP in DSAEK eye. Fortunately, however, the donor tissue adhered to the host corneal stroma without any dislocation and it has been uneventful at following post-operative visits.

At present, there are discussions regarding the endothelial exposure to the air. In fact, some doctors aspirate the air from the anterior chamber just a few minutes after the DSAEK surgery, while most others leave the air as long as possible. In addition, some report DSAEK with C<sub>3</sub>F<sub>8</sub> or SF<sub>6</sub> in place of filtered air [8]. In this air exposure issue, therefore, we have to handle the dilemma of how to balance between the corneal endothelial damages and donor adherence. At this point, it is hard to answer this question clearly, because each case has differences in the donor and host corneal conditions, surgeons' preference, and patient efforts to keep lying down.

Subconjunctival emphysema in this case seemed to be from the temporal-inferior paracentesis incision. We experienced this for the first time, though the DSAEK surgery for this patient was the same as usual. Of course, we may have experienced the air leakage many times without knowing it, because air could leak to the atmosphere, not the subconjunctival space. In that point, emphysema and low IOP worked as good indicators that we could not control the incision and air reduction was faster than humour production.

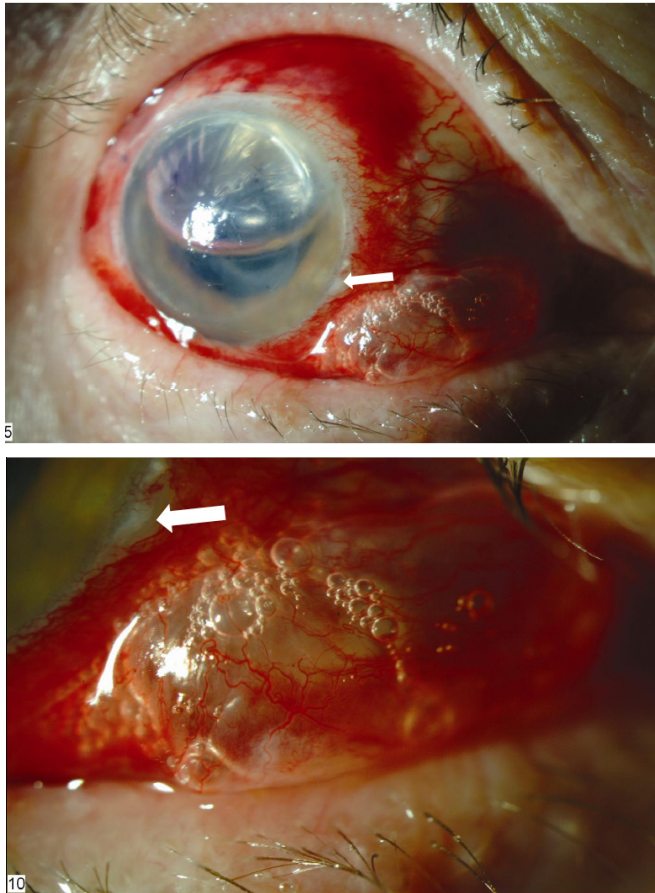
An unstable incision over the subconjunctival sclera part might be beneficial to the corneal endothelium, because air leakage reduces the exposure time, and because the subconjunctival space is much cleaner than outer conjunctiva or cornea.

However, there are three major problems with an unstable incision. The first is that we cannot predict or control the rate of air leakage. The second is that the probability of endophthalmitis might be still higher, either due to a weak wound, or to fluid flow across the cornea and into the

\*Address correspondence to this author at the Bascom Palmer Eye Institute, University of Miami, Miami, FL 33136, USA; E-mail: teyede@hotmail.com

anterior chamber resulting from low IOP, or a combination of both. The third is that we could have higher rate of DSAEK dislocation due to soft eye [9].

Even if we favor the early air reduction in the anterior chamber we have to control air volume in the anterior chamber. To avoid this complication, we should do careful inspection of each wound and chamber stability prior to concluding surgery. And if needed, a suture should be placed over the paracentesis.



**Fig. (1).** Subconjunctival emphysema after DSAEK. Subconjunctival air bubbles and reduced air bubbles in AC are seen in the left eye. And paracentesis incision (arrow) can be seen over the subconjunctival sclera.

## ABBREVIATIONS

- DSAEK = Descemet's stripping automated endothelial keratoplasty  
 PKP = Penetrating keratoplasty  
 AC = Anterior chamber  
 IOP = Intraocular pressure

## REFERENCES

- [1] Gorovoy MS. Descemet-stripping automated endothelial keratoplasty. *Cornea* 2006; 25: 886-9.
- [2] Terry MA. Endothelial keratoplasty: history, current state, and future directions. *Cornea* 2006; 25: 873-8.
- [3] Fang JP, Hamill MB. Descemet's stripping endothelial keratoplasty under topical anesthesia. *J Refract Surg* 2007; 33: 187-8.
- [4] Koenig SB, Covert DJ. Early results of small-incision Descemet's stripping and automated endothelial keratoplasty. *Ophthalmology* 2007; 114: 221-6.
- [5] Price FW Jr, Price MO. Descemet's stripping with endothelial keratoplasty in 200 eyes: Early challenges and techniques to enhance donor adherence. *J Refract Surg* 2006; 32: 411-8.
- [6] Olson RJ. Air and the corneal endothelium: An *in vivo* specular microscopy study in cats. *Arch Ophthalmol* 1980; 98: 1283-4.
- [7] Kerr Muir MG, Sherrard ES, Andrews V, et al. Air, methylcellulose, sodium hyaluronate and the corneal endothelium. Endothelial protective agents. *Eye* 1987; 1(Pt 4): 480-6.
- [8] Mearza AA, Qureshi MA, Rostron CK. Experience and 12-month results of Descemet-stripping endothelial keratoplasty (DSEK) with a small-incision technique. *Cornea* 2007; 26: 279-83.
- [9] Price FW Jr, Price MO. A Nonsurgical Treatment for Donor Dislocation After Descemet Stripping Endothelial Keratoplasty (DSEK). *Cornea* 2006; 25: 991.

Received: March 11, 2008

Revised: May 7, 2008

Accepted: May 8, 2008

© Ide et al.; Licensee Bentham Open.

This is an open access article distributed under the terms of the Creative Commons Attribution License (<http://creativecommons.org/licenses/by/2.5/>), which permits unrestricted use, distribution, and reproduction in any medium, provided the original work is properly cited.