



The Open Orthopaedics Journal

Content list available at: www.benthamopen.com/TOORTHJ/

DOI: 10.2174/1874325001812010075



RESEARCH ARTICLE

Preoperative Ultrasonographic Evaluation for Malignancy of Soft-Tissue Sarcoma: A Retrospective Study

Takeshi Morii^{1,*}, Tomonori Kishino², Naoko Shimamori², Mitsue Motohashi², Hiroaki Ohnishi², Keita Honya³, Takayuki Aoyagi¹, Takashi Tajima¹ and Shoichi Ichimura¹

¹Department of Orthopaedic Surgery, Faculty of Medicine, Kyorin University, 6-20-2 Shinkawa, Mitaka, Tokyo181-8611, Japan

²Department of Laboratory Medicine, Faculty of Medicine, Kyorin University, 6-20-2 Shinkawa, Mitaka, Tokyo181-8611, Japan

³Department of Medical Radiological Technology, Faculty of Health Sciences, Kyorin University, 5-4-1 Shimorenjaku, Mitaka, Tokyo181-8612, Japan

Received: December 23, 2017

Revised: February 14, 2018

Accepted: February 23, 2018

Abstract:

Background:

Ultrasonography is useful for distinguishing between benign and malignant soft-tissue tumors. However, no study has focused on its usefulness in the differential diagnosis between low-grade and high-grade soft-tissue sarcomas. We conducted a retrospective study to determine the usefulness of the parameters of ultrasonograph and to develop a practical scoring system for distinguishing between high-grade and low-grade sarcomas.

Methods:

Twenty-two cases of low-grade and 43 cases of high-grade malignant soft-tissue sarcoma were enrolled. Ultrasonography parameters including the longest diameter, depth of the tumor, echogenicity, tumor margin, and vascularity defined according to Giovagnorio's criteria were analyzed as factors to distinguish between the two types of sarcoma. Significant factors were entered into a multivariate model to define the scores for distinction according to the odds ratio. The usefulness of the score was analyzed *via* receiver operating characteristic analyses.

Results:

In univariate analysis, tumor margin, echogenicity, and vascularity were significantly different between low- and high-grade sarcomas. In the multivariate regression model, the odds ratio for high-grade vs. low-grade sarcoma was 8.8 for tumor margin, 69 for echogenicity, and 8.3 for vascularity. Scores for the risk factors were defined as follows: 1, ill-defined margin; 2, hypoechoic echogenicity; and 1, type IV in Giovagnorio's criteria. The sum of each score was confirmed by receiver operating characteristic analysis. The area under the curve was 0.95, with a cut-off score of 3, indicating that the scoring system was useful.

Conclusion:

The ultrasonography parameters of tumor margin, echogenicity, and vascularity are useful for distinguishing between low- and high-grade sarcomas.

Keywords: Soft tissue tumor, Diagnosis, Ultrasonography, High-grade sarcoma, Low-grade sarcoma, Malignancy.

* Address correspondence to this author at the Department of Orthopaedic Surgery, Faculty of Medicine, Kyorin University, Takeshi Morii, 6-20-2 Shinkawa, Mitaka, Tokyo 161-8611, Japan; Tel: +81-422-47-5511; E-mail: t-morii@gb3.so-net.ne.jp

1. INTRODUCTION

Soft-tissue sarcoma is a rare neoplasm of mesenchymal origin. As biological properties, differentiation, histological origin, local invasiveness, sensitivity to radiotherapy and chemotherapy, and incidence of local recurrence and metastasis vary significantly, its treatment should be selected on the basis of the nature of the tumor and should be decided on a case-to-case basis [1 - 4]. The treatment modality is selected based on the histological grade of the tumor determined *via* pathological examination of the specimen from a lesion, which is a representative parameter of tumor activity. The Fédération Nationale des Centres de Lutte Contre le Cancer (FNCLCC) grading system is used for soft-tissue sarcomas defined by tumor differentiation, mitosis count, and tumor necrosis; this system is commonly the basis for making decisions about the use of chemotherapy and definition of surgical margins [5]. For example, neoadjuvant and adjuvant chemotherapy are used only for high-grade sarcoma (FNCLCC grade II and III) under the hypothesis that therapeutic reagents are effective only for sarcoma cells with a high mitotic rate [1]. On the other hand, conservative surgery with a closer surgical margin is used for low-grade sarcomas, as they show less local invasiveness [2, 3]. Thus, the grading of sarcomas is critical in the management of soft-tissue tumors. Importantly, grading without the need for invasive biopsy could help in the management of soft-tissue sarcoma.

As the malignancy of the sarcoma is closely related to the biological behavior of tumor cells, including high growth ability represented by a high mitotic rate, upregulated metabolism, and inhomogeneous component caused by central necrosis, the histological grade could be determined *via* indirect and less-invasive methods that can detect the abnormal biological behavior of tumor cells. For example, Folpe *et al* used fludeoxyglucose positron emission tomography (FDG-PET) to predict the grading of sarcomas; this modality can detect the upregulated metabolism of tumor cells [6]. Similarly, Gruber *et al* reported that the inhomogeneous enhancement pattern of magnetic resonance imaging (MRI), a standard radiological modality for evaluating soft-tissue tumors, was useful for determining the grades of soft-tissue tumors [7].

Ultrasonography (US) is an imaging modality widely used for the evaluation of soft-tissue tumors. It has several advantages over FDG-PET and MRI: it is concise, is economical for private clinics, does not require injections, is less invasive, and is easy to perform on children [8, 9]. US is useful for detecting soft-tissue tumors, specifically for examining its location; shape; margin; size; water component; and condition of vessels including the volume of blood flow, vessel density, and structural abnormality without injection [10 - 16]. In addition, several studies have reported that US is useful for the specific diagnosis of soft-tissue tumors such as neurofibromas [17], dermatofibrosarcoma protuberance [18], synovial sarcoma [19] and well-differentiated liposarcoma/atypical lipomatous tumors [20]. Several previous studies reported that tumor characteristics such as large size, infiltration into the surrounding tissues, inhomogeneous enhancement, abnormal vasculature morphology, upregulated vascularity, and upregulated blood flow are useful for distinguishing between benign and malignant soft-tissue tumors (Table 1), [7, 10 - 14, 16, 21 - 26]. In our previous series, we reported that the maximum size, tumor margin, and vascularity evaluated using US were extracted as significant properties of the malignant soft-tissue tumor [7]. However, to our knowledge, US has not yet been used for grading soft-tissue sarcomas so far. Assuming that tumor malignancy is represented by the above-mentioned biological behaviors, the significant parameters for distinguishing between benign and malignant soft-tissue tumors may be applicable for distinguishing between high-grade and low-grade soft-tissue sarcomas. Therefore, in the present study, we aimed to determine the usefulness of US parameters except for the Sonazoid-enhancement pattern, which is not available for soft-tissue tumors in Japan and to develop a practical scoring system for distinguishing between high-grade and low-grade soft-tissue sarcomas.

Table 1. Previous reports of differential diagnosis between benign and malignant soft tissue tumors.

| Author (Year of publication) | Significant parameters useful for discrimination | Reference |
|------------------------------|--|-----------|
| Giovagnorio F (1999) | Increased vascularization | [13] |
| Belli P (2000) | Irregular margin, Hypoechoic pattern, Increased vascularization, Vessel arrangement, Systolic velocities | [21] |
| Bodner G (2002) | Vessel arrangement, Vessel structure, Minimum/maximum resistive index | [14] |
| Griffith JF (2004) | Vascular organization, End diastolic velocity, Resistive index | [16] |
| Chiou HJ (2009) | Infiltrated margins, Scalloped shape, Size, Ill-defined margin, | [11] |
| Chen CY (2009) | Morphologic and texture feature diagnosed by computer-aided diagnosis system | [22] |
| Chiou HJ (2010) | Vascular index, Flow index, Vascular-flow index | [23] |
| Stramare R (2013) | Peak enhancement intensity | [24] |

(Table 1) contd....

| Author (Year of publication) | Significant parameters useful for discrimination | Reference |
|------------------------------|---|-----------|
| Oebisu N (2014) | Size, Depth, Heterogeneous texture, Ill-defined margin, Increased vascularization | [10] |
| Nagano S (2015) | Size, Hypoechoic pattern, Heterogeneous texture, Increased vascularization, | [12] |
| De Marchi A (2016) | Inhomogeneous perfusion, Arterial uptake | [25] |
| Gruber L (2016) | Inhomogeneous contrast enhancement | [7] |
| Morii T (2018) | Size, Ill-defined margin, Increased vascularization | [26] |

2. MATERIALS AND METHODS

To evaluate the value of US parameters to the differential diagnoses of low-grade and high-grade sarcomas, this retrospective uncontrolled study examined data from the medical records of patients with sarcomas. The inclusion criteria were as follows: pathological diagnosis of primary soft-tissue sarcoma; surgical treatment at the authors' institutions between January 2013 and December 2015; performance of preoperative US examination before any intervention including biopsy; and availability of clinical, pathological, and radiological data. A total of 65 patients (30 men, 35 women) with soft-tissue sarcomas were enrolled. The mean and median ages were 61 years and 64 years, respectively. The pathological diagnoses were as follows: liposarcoma in 30 cases, undifferentiated pleomorphic sarcoma in 14 cases, myxofibrosarcoma in 5 cases, malignant peripheral nerve sheath tumor in 5 cases, leiomyosarcoma in 2 cases, dermatofibrosarcoma protuberance in 2 cases, and others in 7 cases. Cases were classified according to the FNCLCC grading system [5] as follows: grade I, 22 cases; grade II, 15 cases; and grade III, 28 cases. In the present study, grade I was defined as a low grade, and grades II and III were defined as high grades (Table 2).

Table 2. Histological diagnosis of the subjects.

| Diagnosis | Low grade | High grade | Total |
|---------------------|-----------|------------|-------|
| LS | 18 | 12 | 30 |
| WDLS | 17 | 0 | 17 |
| Myxoid LS | 1 | 6 | 7 |
| Pleomorphic LS | 0 | 1 | 1 |
| Dedifferentiated LS | 0 | 5 | 5 |
| UPS | 0 | 14 | 14 |
| Myxofibrosarcoma | 0 | 5 | 5 |
| MPNST | 0 | 5 | 5 |
| Leiomyosarcoma | 0 | 2 | 2 |
| DFSP | 2 | 0 | 2 |
| Others | 2 | 5 | 7 |
| Total | 22 | 43 | 65 |

LS, liposarcoma; WDLS, well-differentiated liposarcoma; UPS, undifferentiated pleomorphic sarcoma; MPNST, malignant peripheral nerve sheath tumor; DFSP, dermatofibrosarcoma protuberance.

The US was performed before any intervention, including open biopsy, radiotherapy, chemotherapy, and resection, by using an Aplio 500 ultrasound scanner (Toshiba Medical Systems, Tochigi, Japan). All US examinations were performed using linear (10 MHz) and convex (3.5 MHz) transducers.

We selected several independent variables evaluated *via* US, such as the longest diameter, depth of the tumor, echogenicity, tumor margin, and tumor vascularity, which are significant factors in distinguishing between benign and malignant soft-tissue tumors [10, 12 - 14, 16, 21]. The gray-scale US was used to evaluate the longest diameter, depth of the tumor (deep/subcutaneous), echogenicity, and tumor margin. Echogenicity was defined as hypoechoic or hyperechoic/isoechoic, relative to the adjacent muscle tissue [10, 21]. Tumor margins were defined as per previous reports: well-defined (clear-cut and thin, capsule-like) or ill-defined (uncertain margin with respect to adjacent normal tissue or certain irregular margin with respect to adjacent normal tissue and wider transitional zones) (Fig. 1) [10, 11]. Doppler sonography was used to evaluate tumor vascularity based on Giovagnorio's criteria [13]. In brief, the vascularity patterns were classified as avascular (type I), hypovascular with a single vascular pole in the hilum (type II), hypervascular with multiple peripheral poles (type III) (Figs. 1C and 1E), or hypervascular with internal vessels (type IV) (Figs. 1A, 1B and 1D). In the present study, the vascularity pattern was considered a continuous variable. Gray-scale US in combination with Doppler US was prospectively performed by either one of two investigators (N.S. and M.M.), who were blinded to the patient data and final histological diagnosis.

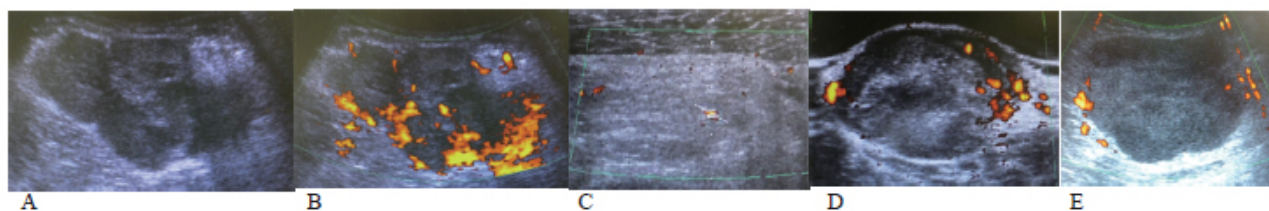


Fig. (1). Representative ultrasonography findings of patients in this study. Grade III undifferentiated pleomorphic sarcoma in the thigh (67-year-old man). Hypoechoic, ill-defined, infiltrating margin (A) with prominent vascularization (Giovagnorio's criteria type VI) (B). A score of 4 is assigned, indicating high-grade tumor (true positive). (C.) Grade I well-differentiated liposarcoma in the buttock (52-year-old man). Hyperechoic mass and undefined margin with limited marginal vascularity (Giovagnorio's criteria type III). A score of 1 is assigned, indicating low-grade tumor (true negative). (D.) Grade I dermatofibrosarcoma protuberance in the shoulder (34-year-old man). Hyperechoic, well-defined margin with prominent vascularization (Giovagnorio's criteria type VI). A score of 1 is assigned, indicating low-grade sarcoma (true negative). (E.) Grade III malignant peripheral nerve sheath tumor in the abdomen wall (74-year-old man). Hypoechoic, well-defined margin with limited marginal vascularity (Giovagnorio's criteria type III). A score of 2 is assigned, indicating low-grade sarcoma (false negative).

The chi-squared, Fisher's exact, and Mann–Whitney *U*-tests were used in the univariate analyses for comparing each parameter between the low-grade and high-grade groups. The cut-off values were evaluated using receiver operating characteristic (ROC) analyses, with the significant factors included as continuous variables. Variables that were significant in univariate analyses ($p < 0.05$) were entered into a multivariate logistic regression model. Based on the odds ratio determined by the regression model, we established a scoring system to distinguish between the low-grade and high-grade groups. Statistical analyses were performed using JMP software (version 10; SAS Institute Inc., Cary, North Carolina, USA). All procedures were performed in accordance with the ethical standards of the responsible committee on human experimentation (institutional and national) and the Helsinki Declaration of 1964 and later versions. The study was approved by the institutional review board of the authors' institution.

3. RESULT

The longest diameter, depth of the tumor, tumor margin, echogenicity, and vascularity evaluated using US were compared between the low-grade and high-grade groups *via* univariate analysis. The results showed that tumor margin ($p = 0.005$), echogenicity ($p < 0.0001$), and vascularity ($p < 0.0001$) were significantly different (Table 3) between the two groups. ROC analysis performed to determine the most useful cut-off value of Giovagnorio's criteria for distinguishing between the two groups showed that a cut-off value of 4 was the most appropriate (Fig. 2A), with a sensitivity and specificity of 0.91 and 0.41, respectively. The area under the curve of 0.75 indicated that the cut-off value was useful for determining the malignancy of the tumor.

Table 3. Results of the univariate analyses of ultrasonography parameters for comparing low-grade and high-grade sarcomas.

| Findings | Low grade | High grade | p value |
|---------------------------|------------|------------|---------|
| The longest diameter (mm) | 118 ± 71* | 107 ± 46* | 0.80 |
| Depth | | | 0.57 |
| Subcutaneous | 6 | 15 | |
| Deep | 14 | 21 | |
| Margin | | | 0.005 |
| Well-defined | 17 | 17 | |
| Ill-defined | 5 | 26 | |
| Echogenicity | | | <0.0001 |
| Hypoechoic | 2 | 37 | |
| Iso/Hyperechoic | 20 | 6 | |
| Vascularity | | | |
| As continuous variable | 3.1 ± 0.9* | 3.9 ± 0.5* | <0.0001 |
| Type I | 1 | 1 | <0.0001 |

| Findings | Low grade | High grade | p value |
|----------|-----------|------------|---------|
| Type II | 4 | 0 | – |
| Type III | 8 | 3 | – |
| Type IV | 9 | 39 | – |

*, mean ± standard deviation

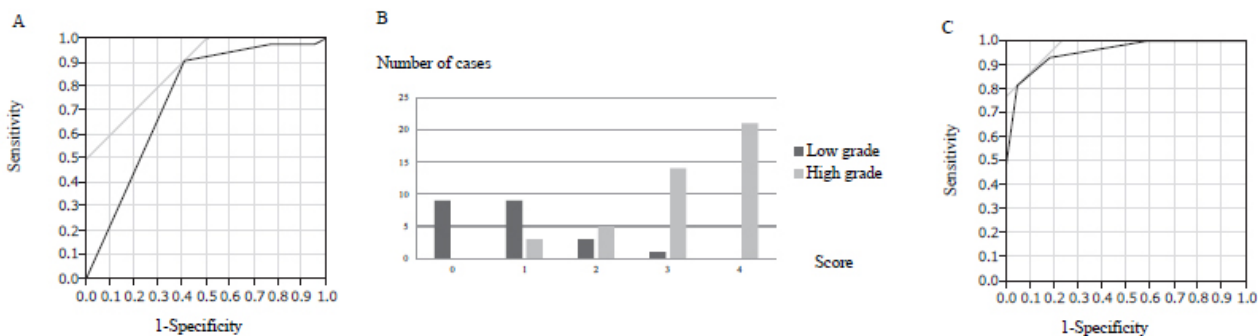


Fig. (2). A. Receiver operating characteristic (ROC) curve for the cut-off value for Giovagnorio’s criteria to distinguish between low-grade and high-grade sarcomas. B. Distribution of low-grade and high-grade cases according to the score. C. ROC curve to determine the cut-off score for low-grade and high-grade sarcomas.

The three significant parameters were subsequently entered into a logistic regression model. Multivariate analysis showed that the three variables (margin, echogenicity, and vascularity) were independent risk factors (Table 4). The odds ratio for high-grade vs. low-grade sarcomas was 8.8 for tumor margin, 69 for echogenicity, and 8.3 for vascularity. Based on these ratios, we established a scoring system to distinguish between low-grade and high-grade sarcomas according to the US findings (Table 5). The prognostic score was calculated by adding all the scores of individual factors. Each case was scored from 0 to 4 points (Fig. 2B). The scores of low-grade and high-grade sarcomas (mean ± standard deviation) were 0.8 ± 0.8 and 3.2 ± 0.9, respectively. Most cases of low-grade sarcomas were scored <2, whereas most cases of high-grade sarcomas were scored >3. The scores of high-grade sarcomas were significantly higher than those of low-grade sarcomas (p < 0.0001). Finally, we plotted the ROC curve for this model (Fig. 2C). The cut-off value of the score to distinguish between low-grade and high-grade sarcomas was determined to be 3, with a sensitivity and specificity of 0.81 and 0.95, respectively. The area under the curve of 0.95 indicated that the cut-off was useful for determining malignancy of the tumor in terms of tumor margin, echogenicity, and vascularity.

Table 4. Results of multivariate analyses of ultrasonography parameters for comparing low-grade and high-grade sarcomas.

| Findings | p value | Odds ratio | 95% CI |
|-----------------|----------|------------|--------|
| Margin | – | – | – |
| Well-defined | – | Reference | – |
| Ill-defined | 0.02 | 8.8 | 1.4–87 |
| Echogenicity | – | – | – |
| Iso/Hyperechoic | – | Reference | – |
| Hypoechoic | < 0.0001 | 69 | 11–856 |
| Vascularity | – | – | – |
| Type I/II/III | – | Reference | – |
| Type IV | 0.02 | 8.3 | 1.3–74 |

CI, confidence interval

Table 5. Scoring system based on the odds ratios in multivariate analysis.

| Independent risk factor | Score |
|-------------------------|-------|
| Margin | – |
| Well-defined | 0 |
| Ill-defined | 1 |
| Echogenicity | – |

| Independent risk factor | Score |
|-------------------------|-------|
| Iso/Hyperechoic | 0 |
| Hypoechoic | 2 |
| Vascularity | - |
| Type I/II/III | 0 |
| Type IV | 1 |

4. DISCUSSION

In the present study, we demonstrated the usefulness of US for differential diagnosis between low-grade and high-grade soft-tissue sarcomas. In addition, three significant factors were found to be useful for this distinction: tumor margin, echogenicity, and vascularity.

Chou *et al* defined ill-defined and infiltrated margins as uncertain margins with respect to adjacent normal tissue and certain irregular margin with respect to adjacent normal tissue and wider transitional zone, respectively. These parameters were useful for distinguishing between certain malignant soft-tissue tumors from benign lesion [11]. Similarly, Oebisu *et al* defined ill-defined margins as uncertain margins with respect to adjacent normal tissue and reported that the frequency of ill-defined margin was significantly higher in malignant soft-tissue tumors than in benign lesions [10]. The infiltration trend was histologically confirmed to be the characteristic of malignant soft-tissue tumors. In MRI, the infiltration pattern of expanding along with the fascia or neurovascular or musculature plane around the soft-tissue sarcoma is known as “tail-like pattern”, and this abnormal shadow was pathologically proven to be infiltrating viable cells or edematous change [27, 28]. Even if the “tail-like pattern” is not seen around sarcomas, viable tumor cells are frequently seen outside the margin of the tumor mass [28]. Considering that benign soft-tissue tumors rarely involve local recurrence with intralesional or marginal resection, infiltration is a universal characteristic of malignant soft-tissue sarcoma. Although histological confirmation of the infiltration pattern on US is needed, an ill-defined margin in US can be considered to represent the invasiveness of malignant soft-tissue sarcoma.

Upregulated vascularity is also a universal characteristic of malignant tumors [13, 29]. Upregulated metabolism in the process of non-physiological cell proliferation causes hypoxic conditions around the tumor, resulting in the activation of hypoxia-inducible factor 1 (HIF-1), a transcription factor that is critical in the adaptive cellular response to hypoxia. HIF-1 activates several intracellular signaling pathways for cellular metabolism, angiogenesis, proliferation, and survival by activating related genes including vascular endothelial growth factor (*VEGF*), which promote tumor angiogenesis [30]. As *VEGF* promotes many aspects including an increase in the number of vessels and structural abnormalities, variation in caliber, a non-hierarchical network, lack of smooth muscle cells, disturbed pericapillary architecture, and incomplete vessel walls can be seen in non-physiological tumor angiogenesis [31]. US can easily and non-invasively detect such abnormalities in angiogenesis in the tumor, and therefore, it is broadly applied for distinguishing malignant soft-tissue tumors from benign lesions [10, 12 - 14, 16, 21, 22]. Moreover, in the previous report, we hypothesized that intraoperative blood loss during resection of malignant soft tissue tumor could be predicted using blood flow parameters evaluated *via* US, and showed that vessel density and time-averaged flow velocity could predict the need for intraoperative blood transfusion [32]. However, in terms of grading sarcomas, immunohistochemical studies for markers of vessels or proteins of pro-angiogenic markers, such as HIF-1 and VEGF, or markers for a hypoxic condition such as carbonic anhydrase 9 or glucose transporter-1 [33] have been reported to be useful, rather than US. The present study aimed to determine whether US can be used for distinguishing between low-grade and high-grade sarcomas by examining the differences in their biological properties. Our results showed that, at least with respect to the angiogenesis status, immunohistochemical analyses compliment the capability of US, thereby supporting our results.

The usefulness of echogenicity, which is one of the significant factors for distinguishing between low-grade and high-grade sarcoma in the present study, for distinguishing between benign and malignant soft-tissue tumors is controversial. Nagano *et al* reported that low echogenicity was a significant characteristic of malignant soft-tissue tumors [12], whereas Oebisu and Chous reported that echogenicity was not a useful parameter for this distinction [10, 11]. Futani *et al* aimed to differentiate between lipoma and well-differentiated liposarcoma (WDLS), and reported that although the distinction was possible by evaluating the angiogenic conditions using Doppler US, no difference in gray-scale findings including echogenicity between the lipoma and WDLS was confirmed [20], suggesting that non-hypoechoic echogenicity was a common finding in both lipoma and low-grade WDLS. As such, hypoechoic echogenicity is a specific property of high-grade sarcoma rather than malignant soft-tissue sarcoma. In the present study, 16 of the 17 WDLS cases, and all 2 dermatofibrosarcoma protuberance cases, which is another representative

low-grade sarcoma, did not show hypoechoic echogenicity.

The most critical limitation of the present study is that the result of the grading system is disease dependent, *i.e.* the distinction between low-grade and high-grade sarcomas with the same histological diagnosis was not confirmed. A large proportion of low-grade sarcomas are WDLS. Thus, our results may have been from the specific properties of WDLS in US findings, rather than those with low-grade sarcomas. Therefore, a large number of cases of specific histological subtypes with different grades are needed in the future. In addition, future studies should aim to determine what ill-defined margins or hypoechoic echogenicity represent in biological processes. Considering the infiltrating trend as a universal characteristic of malignancy and upregulated frequency of ill-defined margin in malignant tumors, particularly in high-grade sarcomas, an ill-defined margin might reflect an invasive process, but this assumption lacks histological confirmation. Similarly, the biological process underlying hypoechoic echogenicity should be determined in the future.

CONCLUSION

Distinction between high-grade and low-grade sarcoma is possible using US, considering the following parameters: tumor margin, echogenicity, and vascularity.

ETHICS APPROVAL AND CONSENT TO PARTICIPATE

The study was approved by the Institutional Review Board (IRB) of the authors' institution.

HUMAN AND ANIMAL RIGHTS

All procedures were performed in accordance with the ethical standards of the responsible committee on human experimentation (institutional and national) and the Helsinki Declaration of 1964 and later versions.

CONSENT FOR PUBLICATION

Written informed consent was obtained from all participants.

CONFLICT OF INTEREST

The authors declare no conflict of interest, financial or otherwise.

ACKNOWLEDGEMENTS

This research was supported by the Practical Research for Innovative Cancer Control from the Japan Agency for Medical Research and Development.

REFERENCES

- [1] Kataoka K, Tanaka K, Mizusawa J, *et al.* A randomized phase II/III trial of perioperative chemotherapy with adriamycin plus ifosfamide versus gemcitabine plus docetaxel for high-grade soft tissue sarcoma: Japan Clinical Oncology Group Study JCOG1306. *Jpn J Clin Oncol* 2014; 44(8): 765-9. [<http://dx.doi.org/10.1093/jjco/hyu080>] [PMID: 24916336]
- [2] Yamamoto N, Hayashi K, Tanzawa Y, *et al.* Treatment strategies for well-differentiated liposarcomas and therapeutic outcomes. *Anticancer Res* 2012; 32(5): 1821-5. [PMID: 22593468]
- [3] Kubo T, Sugita T, Shimose S, Arihiro K, Ochi M. Conservative surgery for well-differentiated liposarcomas of the extremities adjacent to major neurovascular structures. *Surg Oncol* 2006; 15(3): 167-71. [<http://dx.doi.org/10.1016/j.suronc.2006.11.004>] [PMID: 17184990]
- [4] Sawamura C, Matsumoto S, Shimoji T, Tanizawa T, Ae K. What are risk factors for local recurrence of deep high-grade soft-tissue sarcomas? *Clin Orthop Relat Res* 2012; 470(3): 700-5. [<http://dx.doi.org/10.1007/s11999-011-2017-5>] [PMID: 21826540]
- [5] Trojani M, Contesso G, Coindre JM, *et al.* Soft-tissue sarcomas of adults; study of pathological prognostic variables and definition of a histopathological grading system. *Int J Cancer* 1984; 33(1): 37-42. [<http://dx.doi.org/10.1002/ijc.2910330108>] [PMID: 6693192]
- [6] Folpe AL, Lyles RH, Sprouse JT, Conrad EU III, Eary JF. (F-18) fluorodeoxyglucose positron emission tomography as a predictor of pathologic grade and other prognostic variables in bone and soft tissue sarcoma. *Clin Cancer Res* 2000; 6(4): 1279-87. [PMID: 10778952]

- [7] Gruber L, Loizides A, Luger AK, *et al.* Soft-Tissue Tumor Contrast Enhancement Patterns: Diagnostic Value and Comparison Between Ultrasound and MRI. *AJR Am J Roentgenol* 2017; 208(2): 393-401. [<http://dx.doi.org/10.2214/AJR.16.16859>] [PMID: 27959625]
- [8] Hung EH, Griffith JF. Pitfalls in ultrasonography of soft tissue tumors. *Semin Musculoskelet Radiol* 2014; 18(1): 79-85. [<http://dx.doi.org/10.1055/s-0034-1365837>] [PMID: 24515884]
- [9] Brammer JA, Gubler FM, Maas M, *et al.* Colour Doppler ultrasound predicts chemotherapy response, but not survival in paediatric osteosarcoma. *Pediatr Radiol* 2004; 34(8): 614-9. [<http://dx.doi.org/10.1007/s00247-004-1210-z>] [PMID: 15148555]
- [10] Oebisu N, Hoshi M, Ieguchi M, *et al.* Contrast-enhanced color Doppler ultrasonography increases diagnostic accuracy for soft tissue tumors. *Oncol Rep* 2014; 32(4): 1654-60. [<http://dx.doi.org/10.3892/or.2014.3378>] [PMID: 25109621]
- [11] Chiou HJ, Chou YH, Chiu SY, *et al.* Differentiation of benign and malignant superficial soft-tissue masses using grayscale and color doppler ultrasonography. *J Chin Med Assoc* 2009; 72(6): 307-15. [[http://dx.doi.org/10.1016/S1726-4901\(09\)70377-6](http://dx.doi.org/10.1016/S1726-4901(09)70377-6)] [PMID: 19541566]
- [12] Nagano S, Yahiro Y, Yokouchi M, *et al.* Doppler ultrasound for diagnosis of soft tissue sarcoma: efficacy of ultrasound-based screening score. *Radiol Oncol* 2015; 49(2): 135-40. [<http://dx.doi.org/10.1515/raon-2015-0011>] [PMID: 26029024]
- [13] Giovagnorio F, Andreoli C, De Cicco ML. Color Doppler sonography of focal lesions of the skin and subcutaneous tissue. *J Ultrasound Med* 1999; 18(2): 89-93. [<http://dx.doi.org/10.7863/jum.1999.18.2.89>] [PMID: 10206814]
- [14] Bodner G, Schocke MF, Rachbauer F, *et al.* Differentiation of malignant and benign musculoskeletal tumors: combined color and power Doppler US and spectral wave analysis. *Radiology* 2002; 223(2): 410-6. [<http://dx.doi.org/10.1148/radiol.2232010406>] [PMID: 11997546]
- [15] Hong-Jen Chiou, Yi-Hong Chou, See-Ying Chiou *et al.* Application of 3D Power Doppler Ultrasonography in Soft Tissue Neoplasms. *J Med Ultrasound* 2011; 19(1): 14-9.
- [16] Griffith JF, Chan DP, Kumta SM, Chow LT, Ahuja AT. Does Doppler analysis of musculoskeletal soft-tissue tumours help predict tumour malignancy? *Clin Radiol* 2004; 59(4): 369-75. [<http://dx.doi.org/10.1016/j.crad.2003.11.003>] [PMID: 15041458]
- [17] Tsai WC, Chiou HJ, Chou YH, Wang HK, Chiou SY, Chang CY. Differentiation between schwannomas and neurofibromas in the extremities and superficial body: the role of high-resolution and color Doppler ultrasonography. *J Ultrasound Med* 2008; 27(2): 161-6. [<http://dx.doi.org/10.7863/jum.2008.27.2.161>] [PMID: 18204006]
- [18] Shin YR, Kim JY, Sung MS, Jung JH. Sonographic findings of dermatofibrosarcoma protuberans with pathologic correlation. *J Ultrasound Med* 2008; 27(2): 269-74. [<http://dx.doi.org/10.7863/jum.2008.27.2.269>] [PMID: 18204018]
- [19] Kishino T, Morii T, Mochizuki K, *et al.* Unusual sonographic appearance of synovial sarcoma of the anterior abdominal wall. *J Clin Ultrasound* 2009; 37(4): 233-5. [<http://dx.doi.org/10.1002/jcu.20538>] [PMID: 19035334]
- [20] Futani H, Yamagiwa T, Yasojimat H, Natsuaki M, Stugaard M, Maruo S. Distinction between well-differentiated liposarcoma and intramuscular lipoma by power Doppler ultrasonography. *Anticancer Res* 2003; 23(2C): 1713-8. [PMID: 12820446]
- [21] Belli P, Costantini M, Mirk P, Maresca G, Priolo F, Marano P. Role of color Doppler sonography in the assessment of musculoskeletal soft tissue masses. *J Ultrasound Med* 2000; 19(12): 823-30. [<http://dx.doi.org/10.7863/jum.2000.19.12.823>] [PMID: 11127006]
- [22] Chen CY, Chiou HJ, Chou SY, *et al.* Computer-aided diagnosis of soft-tissue tumors using sonographic morphologic and texture features. *Acad Radiol* 2009; 16(12): 1531-8. [<http://dx.doi.org/10.1016/j.acra.2009.07.024>] [PMID: 19896070]
- [23] Chiou HJ, Chou YH, Chen WM, Chen W, Wang HK, Chang CY. Soft-tissue tumor differentiation using 3D power Doppler ultrasonography with echo-contrast medium injection. *J Chin Med Assoc* 2010; 73(12): 628-33. [[http://dx.doi.org/10.1016/S1726-4901\(10\)70137-4](http://dx.doi.org/10.1016/S1726-4901(10)70137-4)] [PMID: 21145510]
- [24] Stramare R, Gazzola M, Coran A, *et al.* Contrast-enhanced ultrasound findings in soft-tissue lesions: preliminary results. *J Ultrasound* 2013; 16(1): 21-7. [<http://dx.doi.org/10.1007/s40477-013-0005-1>] [PMID: 24046796]
- [25] De Marchi A, Prever EBD, Cavallo F, *et al.* Perfusion pattern and time of vascularisation with CEUS increase accuracy in differentiating between benign and malignant tumours in 216 musculoskeletal soft tissue masses. *Eur J Radiol* 2015; 84(1): 142-50. [<http://dx.doi.org/10.1016/j.ejrad.2014.10.002>] [PMID: 25454097]
- [26] Morii T, Kishino T, Shimamori N, *et al.* Differential diagnosis between benign and malignant soft issue tumors utilizing ultrasound parameters. *J Med Ultrason* 2018; 45(1): 113-9.

- [27] Imanishi J, Slavin J, Pianta M, *et al.* Tail of Superficial myxofibrosarcoma and undifferentiated pleomorphic sarcoma after preoperative radiotherapy *Anticancer Res* 2016; 36(5): 2339-44. [PMID: 27127141]
- [28] Kaya M, Wada T, Nagoya S, *et al.* MRI and histological evaluation of the infiltrative growth pattern of myxofibrosarcoma. *Skeletal Radiol* 2008; 37(12): 1085-90. [<http://dx.doi.org/10.1007/s00256-008-0542-4>] [PMID: 18629459]
- [29] Morioka H, Morii T, Vogel T, Hornicek FJ, Weissbach L. Interaction of plasminogen-related protein B with endothelial and smooth muscle cells in vitro. *Exp Cell Res* 2003; 287(1): 166-77. [[http://dx.doi.org/10.1016/S0014-4827\(03\)00137-X](http://dx.doi.org/10.1016/S0014-4827(03)00137-X)] [PMID: 12799192]
- [30] Karakashev SV, Reginato MJ. Progress toward overcoming hypoxia-induced resistance to solid tumor therapy. *Cancer Manag Res* 2015; 7: 253-64. [PMID: 26316817]
- [31] Munn LL. Aberrant vascular architecture in tumors and its importance in drug-based therapies. *Drug Discov Today* 2003; 8(9): 396-403. [[http://dx.doi.org/10.1016/S1359-6446\(03\)02686-2](http://dx.doi.org/10.1016/S1359-6446(03)02686-2)] [PMID: 12706657]
- [32] Morii T, Kishino T, Shimamori N, *et al.* Preoperative evaluation of intraoperative blood loss during malignant soft tissue tumor resection by ultrasonography. *J Orthop Sci* 2018; Jan 20. pii: S0949-2658(17)30353-6. Epub ahead of print [<http://dx.doi.org/10.1016/j.jos.2017.12.011>] [PMID: 29366631]
- [33] Kim JI, Choi KU, Lee IS, *et al.* Expression of hypoxic markers and their prognostic significance in soft tissue sarcoma. *Oncol Lett* 2015; 9(4): 1699-706. [<http://dx.doi.org/10.3892/ol.2015.2914>] [PMID: 25789026]

© 2018 Morii *et al.*

This is an open access article distributed under the terms of the Creative Commons Attribution 4.0 International Public License (CC-BY 4.0), a copy of which is available at: (<https://creativecommons.org/licenses/by/4.0/legalcode>). This license permits unrestricted use, distribution, and reproduction in any medium, provided the original author and source are credited.